Основные положения

- Патофизиологические аспекты ОЛ
- Современная классификация ОЛ
- Особенности рентгенологической картины при ОЛ
- Алгоритм лечебной программы

Закон Старлинга

$$Jv = Lp\ S\ [\ (Pc - Pi) – \sigma d\ (7\pi c - \pi i)\ ]$$

Jv – скорость транскапилярной фильтрации (cm^3/sec)

Lp – гидродинамическое сопротивление мембран

S – площадь мембран

Pc – легочное капиллярное гидростатическое давление

Pi – интерстициальное гидростатическое давление

πc – онкотическое давление в капиляре

πi – онкотическое давление в интерстиции

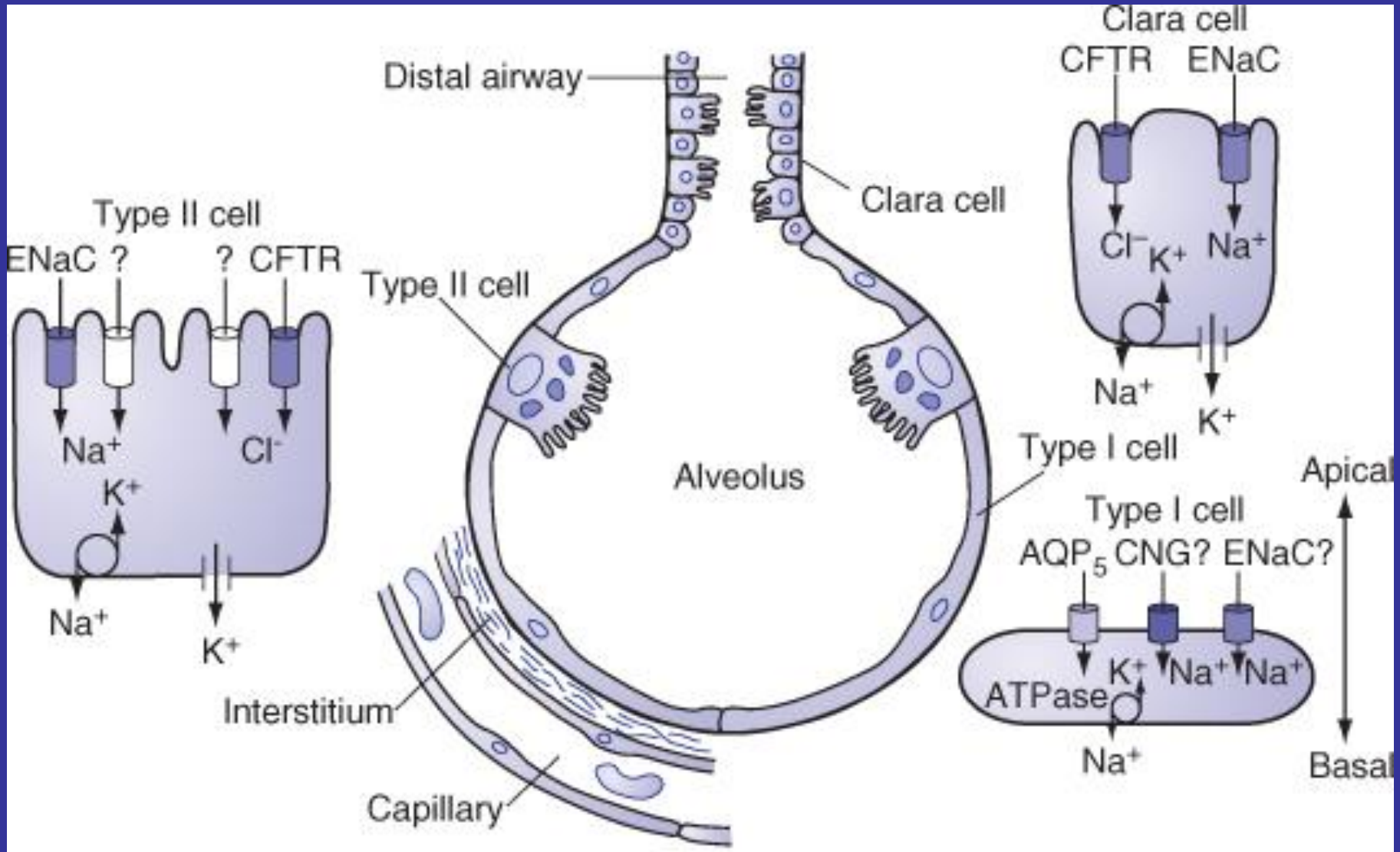

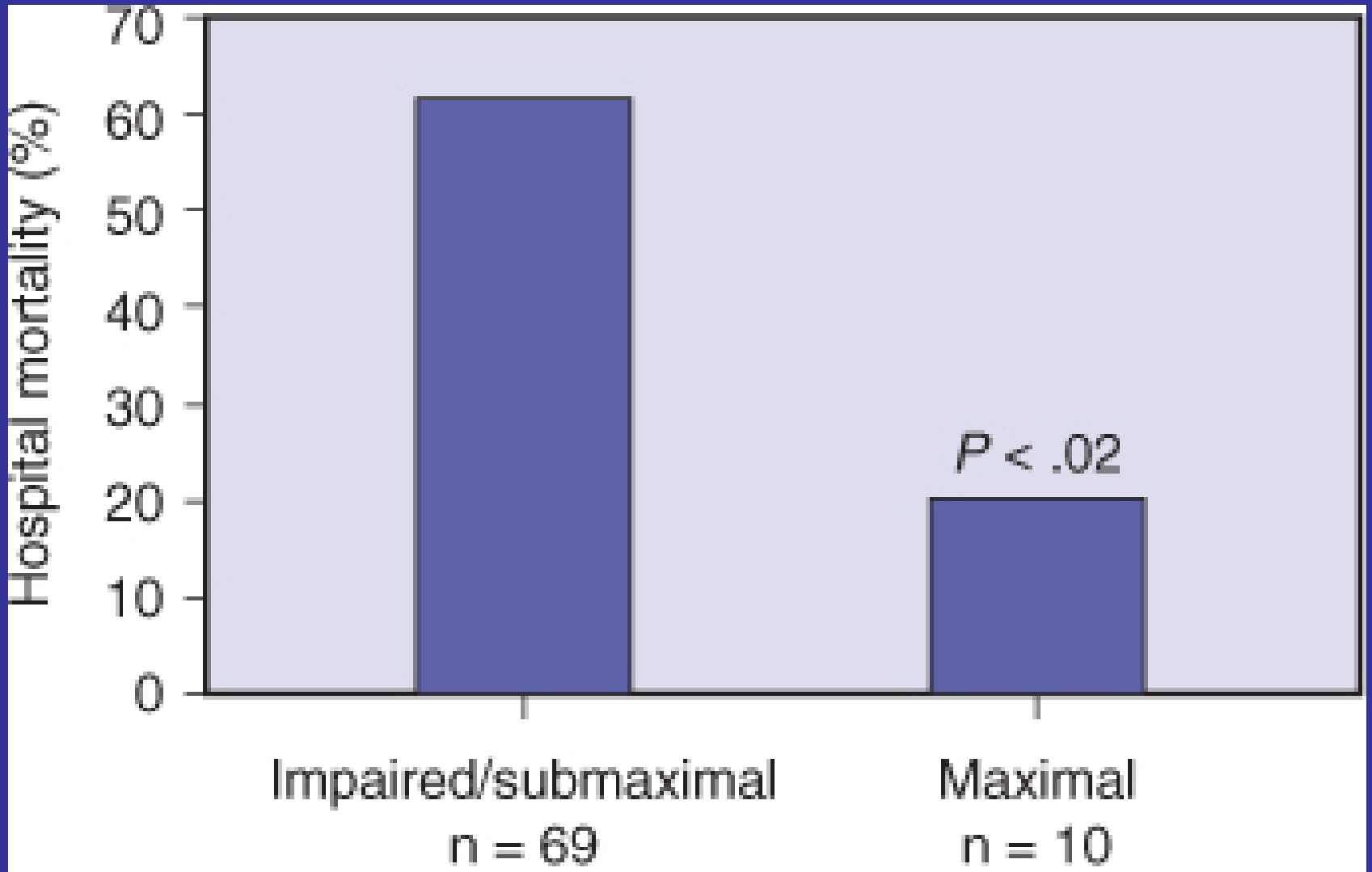

Alveolar fluid clearance

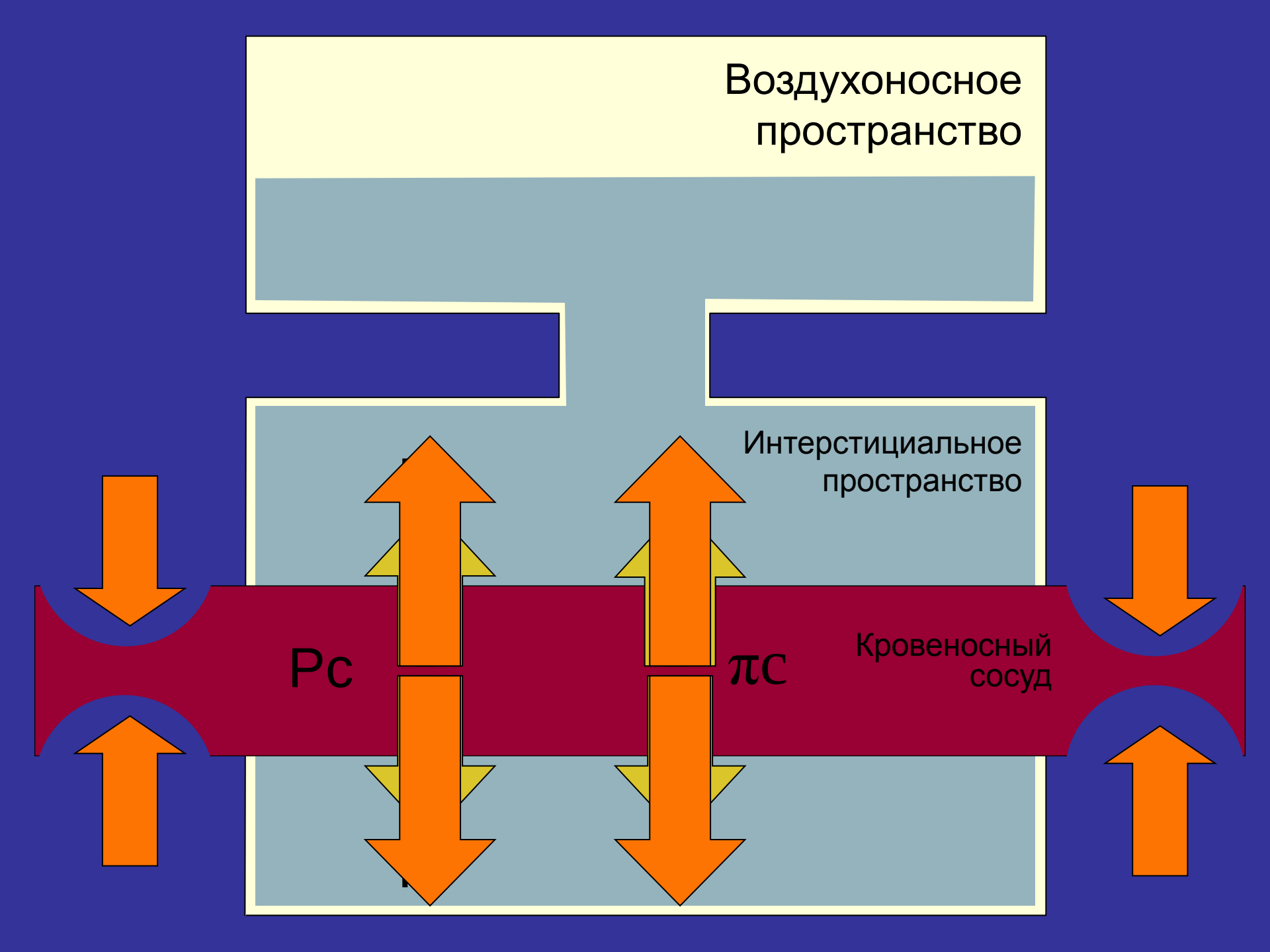
Воздухоносное пространство
Интерстициальное пространство
Pc
πc
Кровеносный сосуд

Вазодилататоры

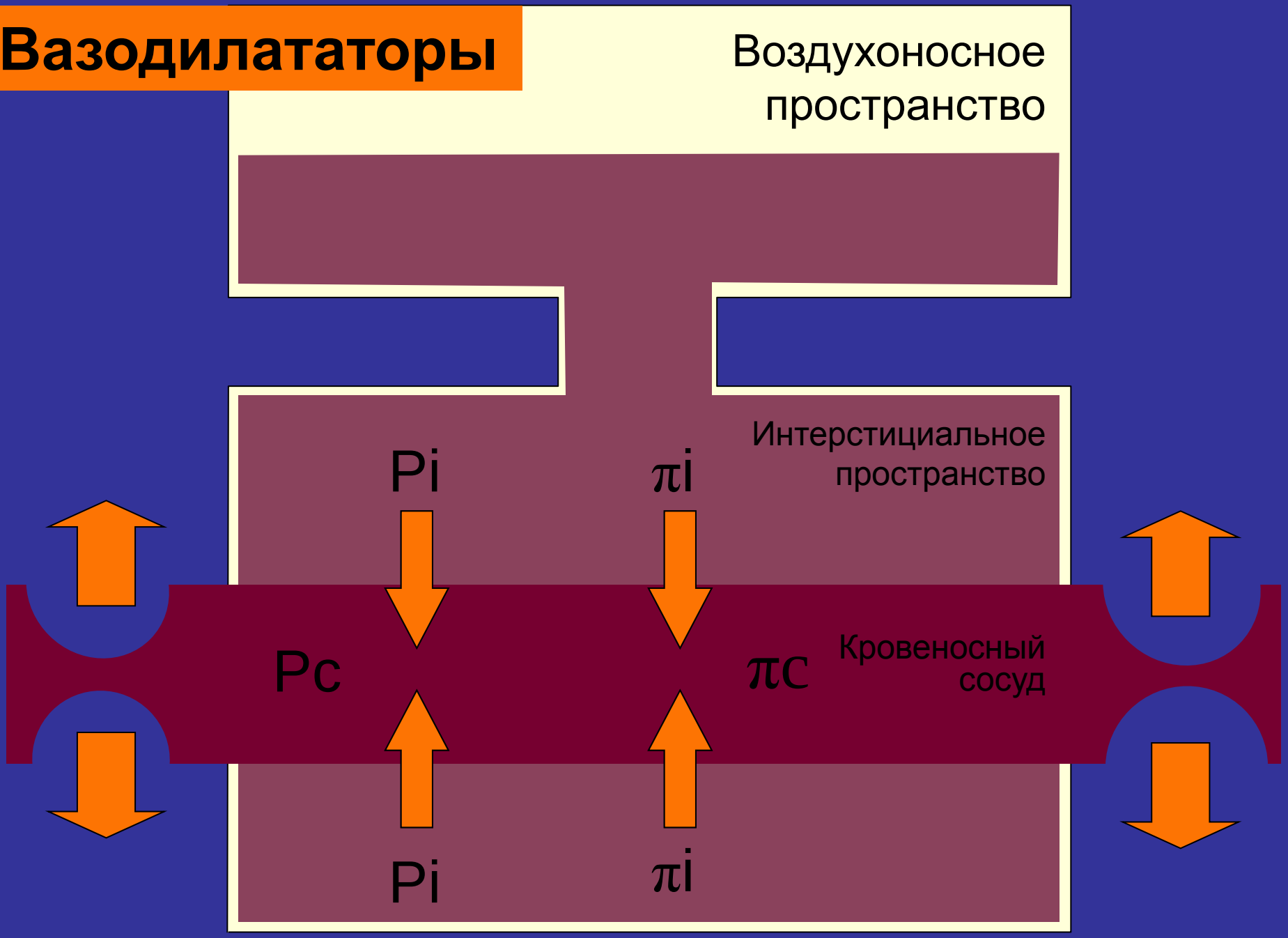

Диуретики

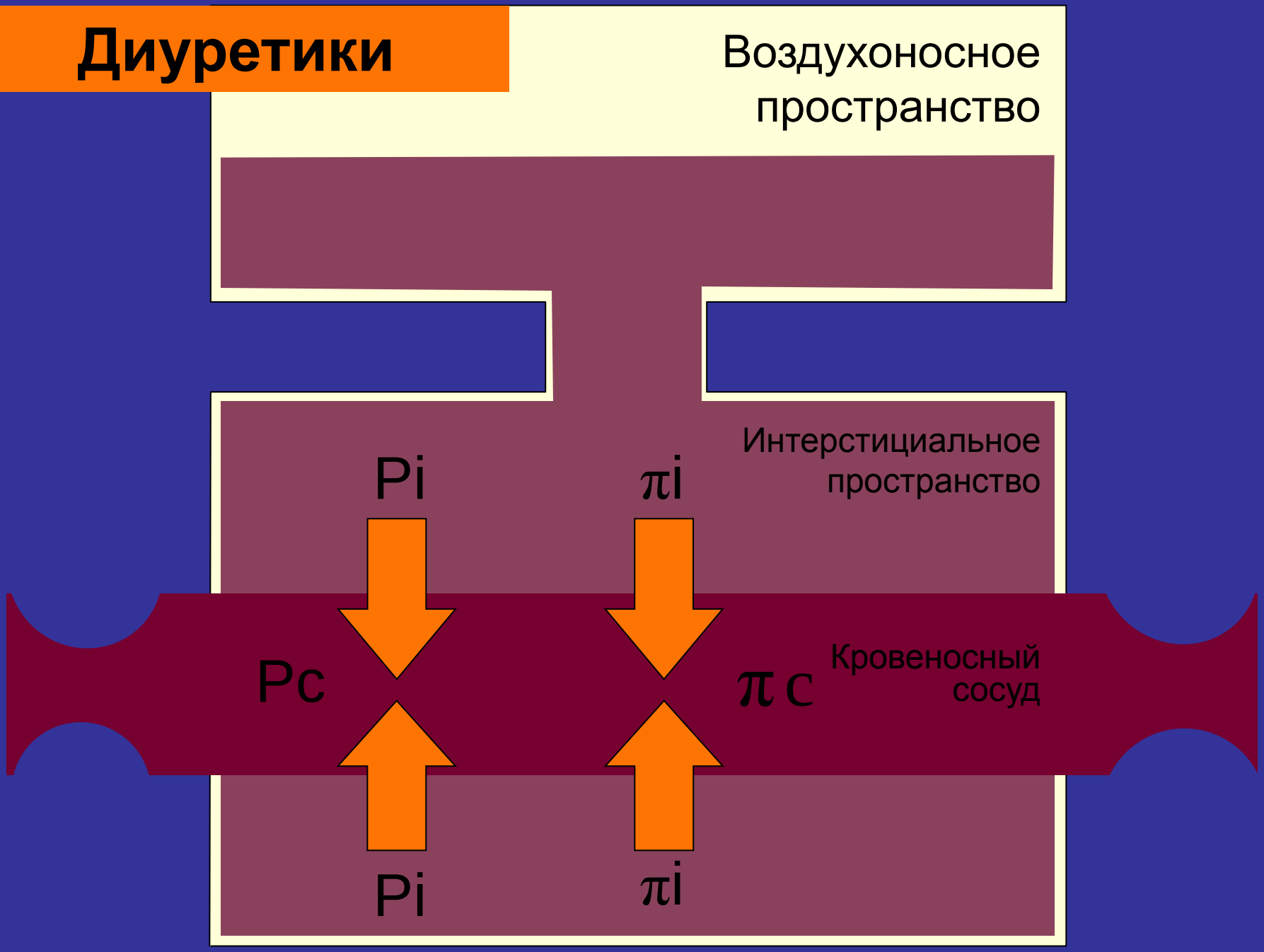
Воздухоносное пространство
Интерстициальное пространство
Pi
πi
Pc
πc
Кровеносный сосуд
Pi
πi

CPAP

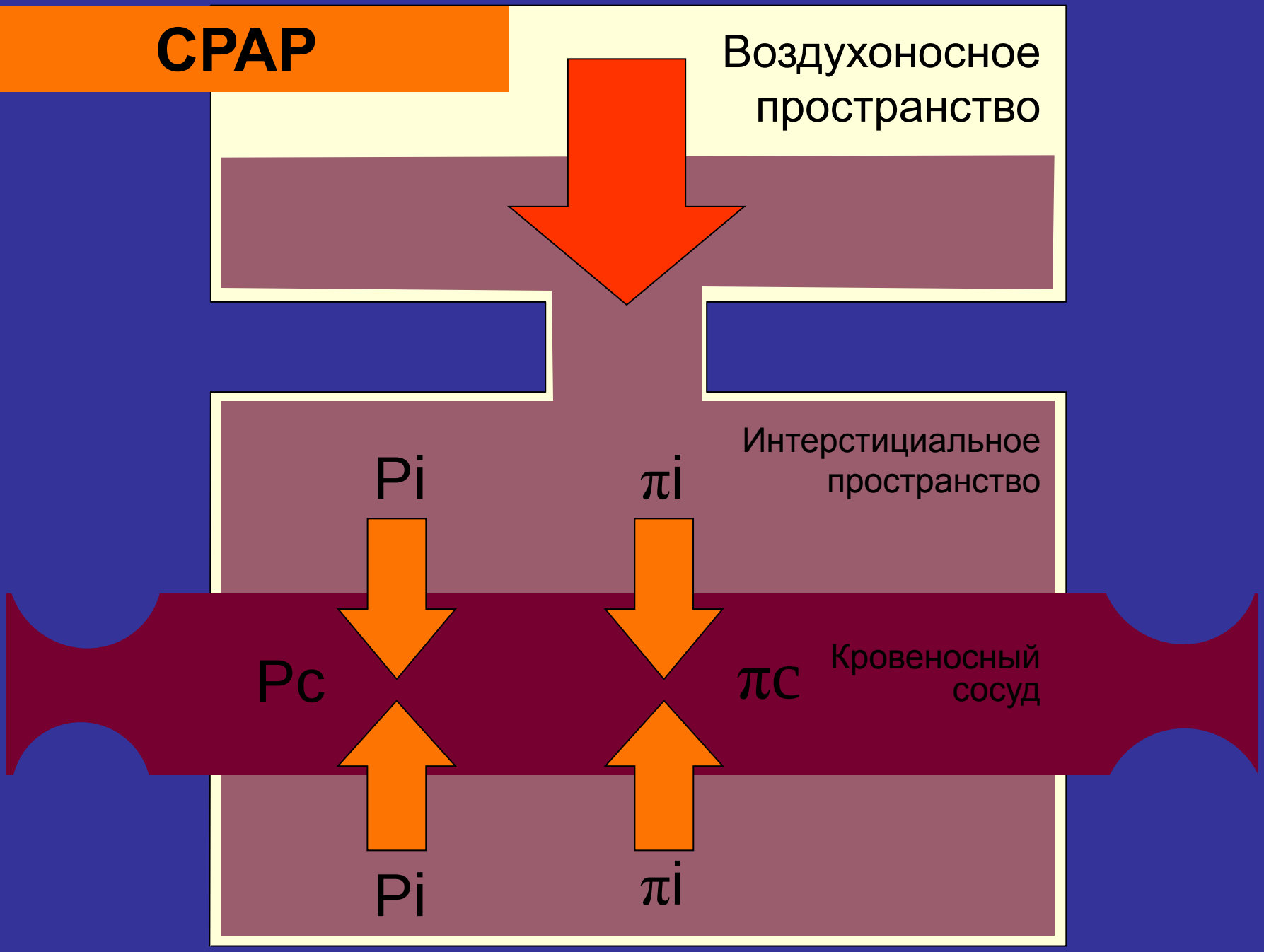
Воздухоносное пространство
Интерстициальное пространство
Pi
πi
Pc
πc
Кровеносный сосуд
Pi
πi

Imaging of Cardiac Failure

Specific Aims

To show how to extract from the chest radiograph important clinical information about central hemodynamics in common clinical conditions leading to right and/or left heart failure: ischemic and valvular heart disease, primary and secondary pulmonary hypertension, overhydration, renal failure, ARDS.

Clinical information from the chest radiograph in patients with right and/or left heart dysfunction

- Evaluation of body fluids balance in ICU patients
- Pulmonary hypertension (idiopathic or secondary to left heart failure, COPD, pulmonary embolism, congenital heart disease)
- Cardiogenic and noncardiogenic pulmonary edema

Radiographic features to analyse and integrate

- Vascular pedicle and azygos vein
- Heart size and shape
- Pulmonary vessels
- Pulmonary edema

Radiographic features to analyse and integrate

- ✓ Vascular pedicle and azygos vein
- Heart size and shape
- Pulmonary vessels
- Pulmonary edema

Vascular pedicle and azygos vein

- changes of circulating blood volume
- changes of central venous pressure

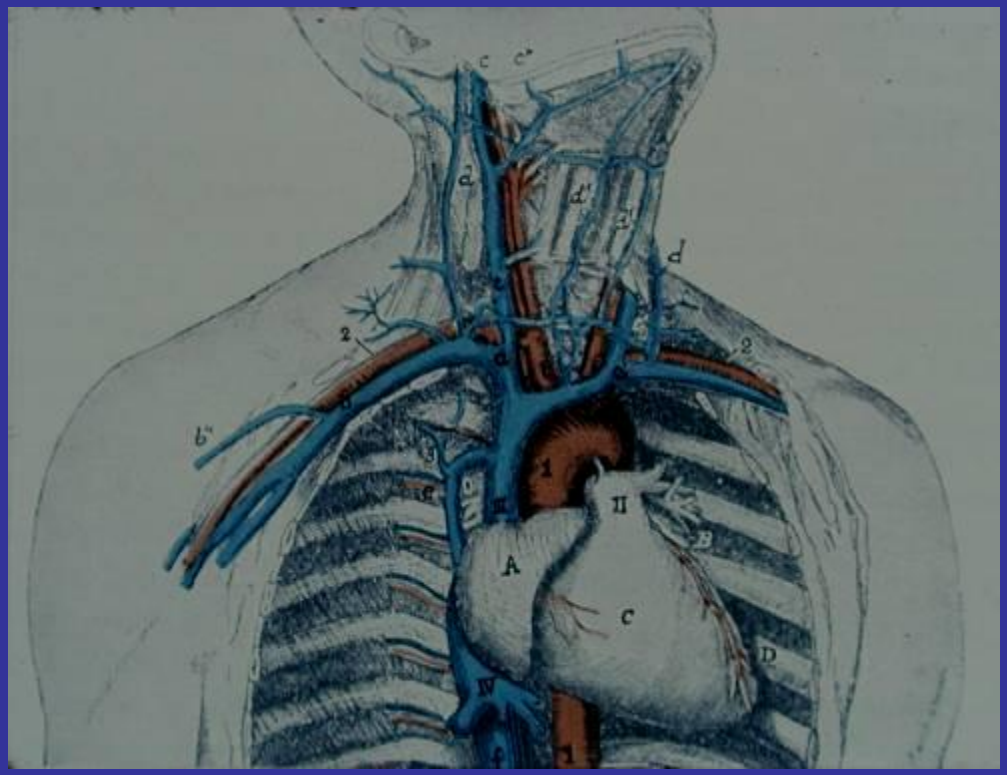

The vascular pedicle of the heart and the vena azygos.

Radiology 1984

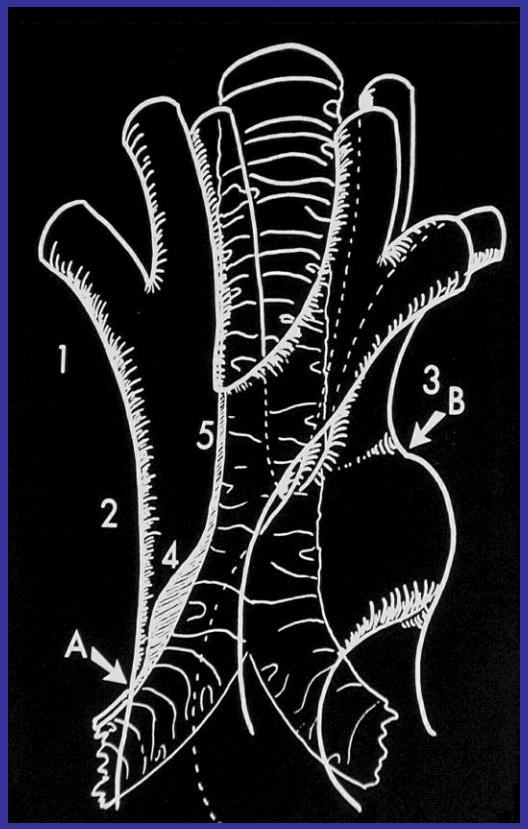

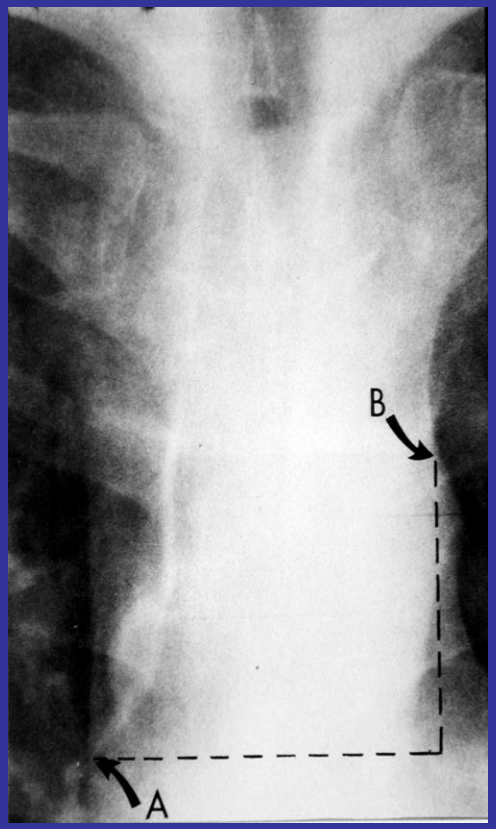

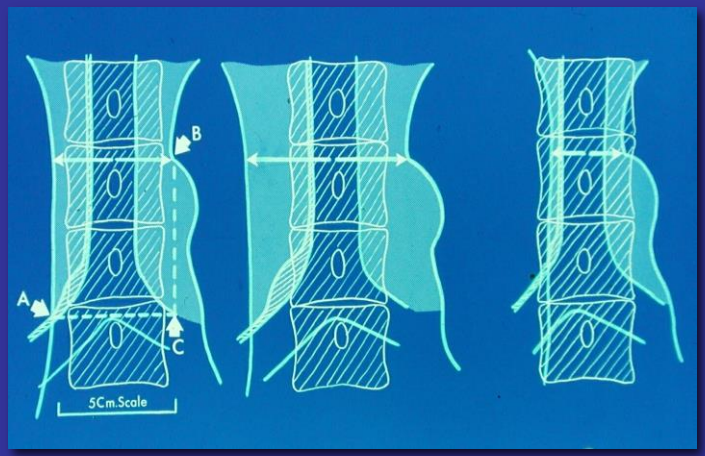

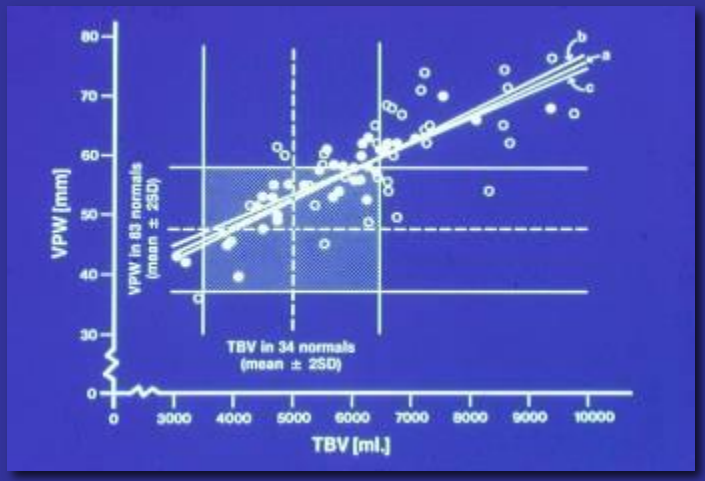

The vascular pedicle of the heart and the vena azygos.

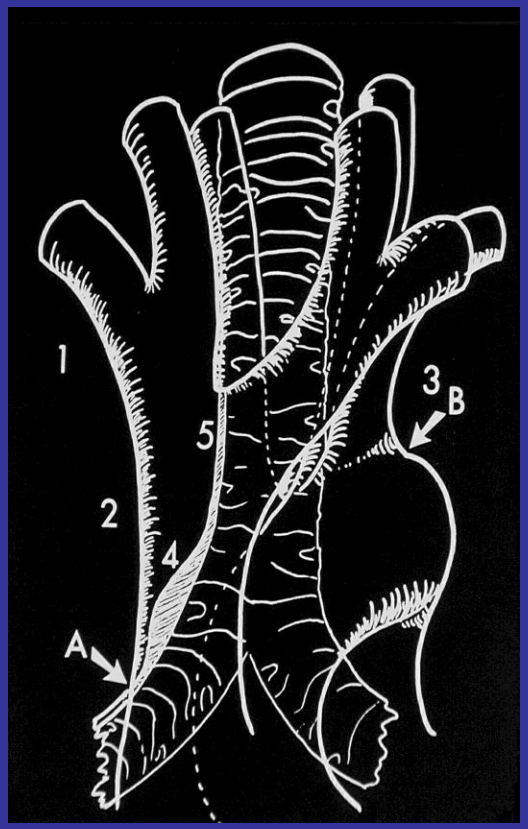

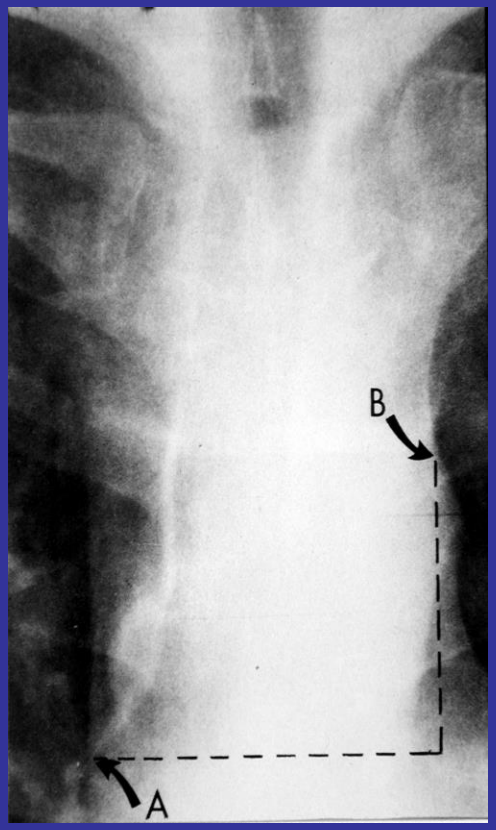

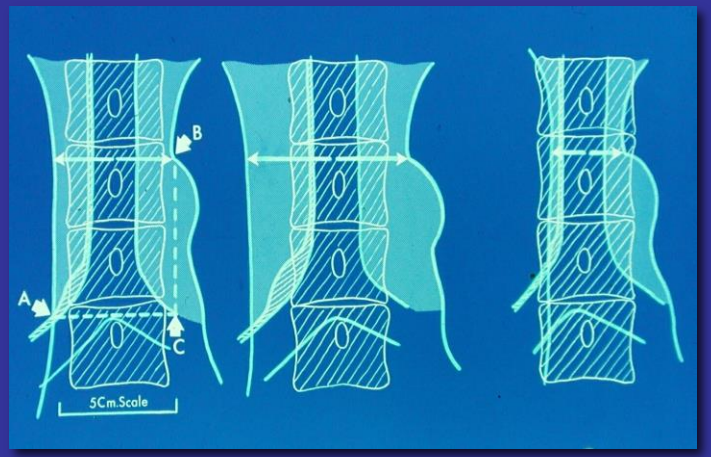

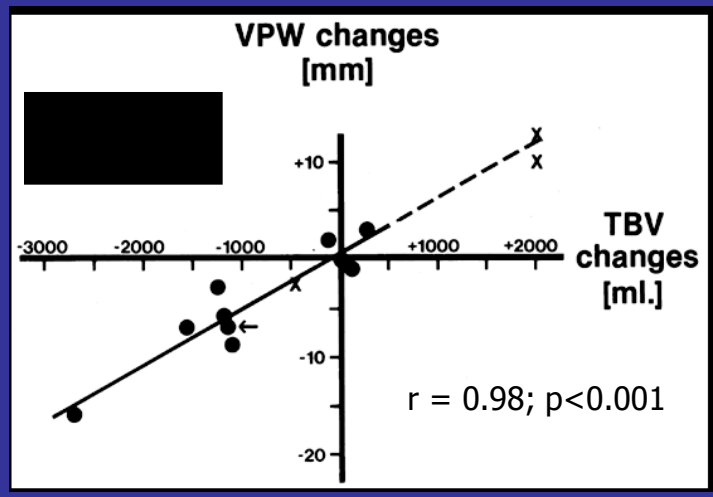

Vascular pedicle and azygos vein

Overhydration

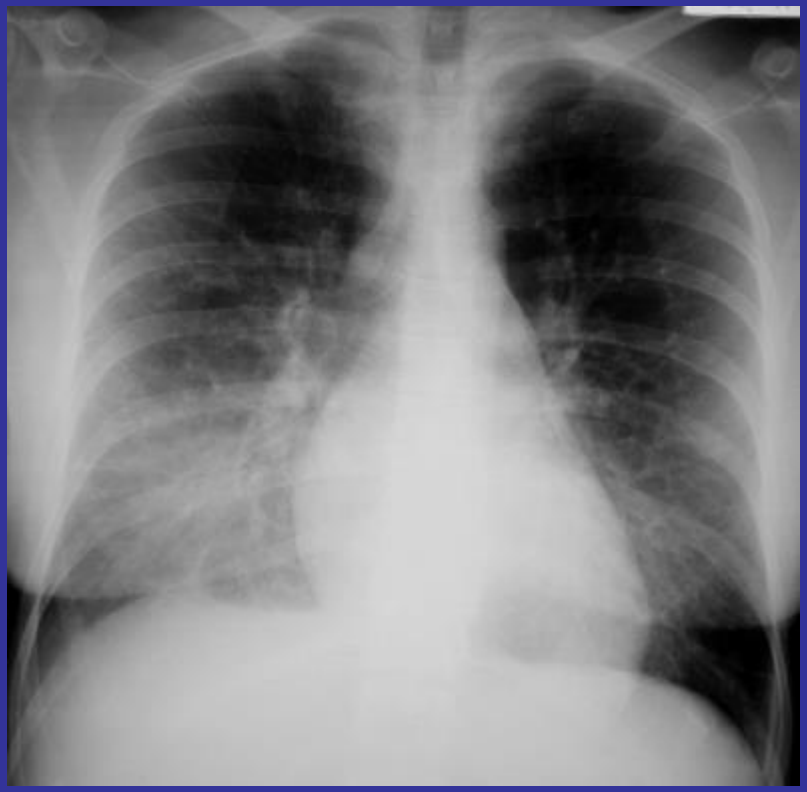

При поступлении

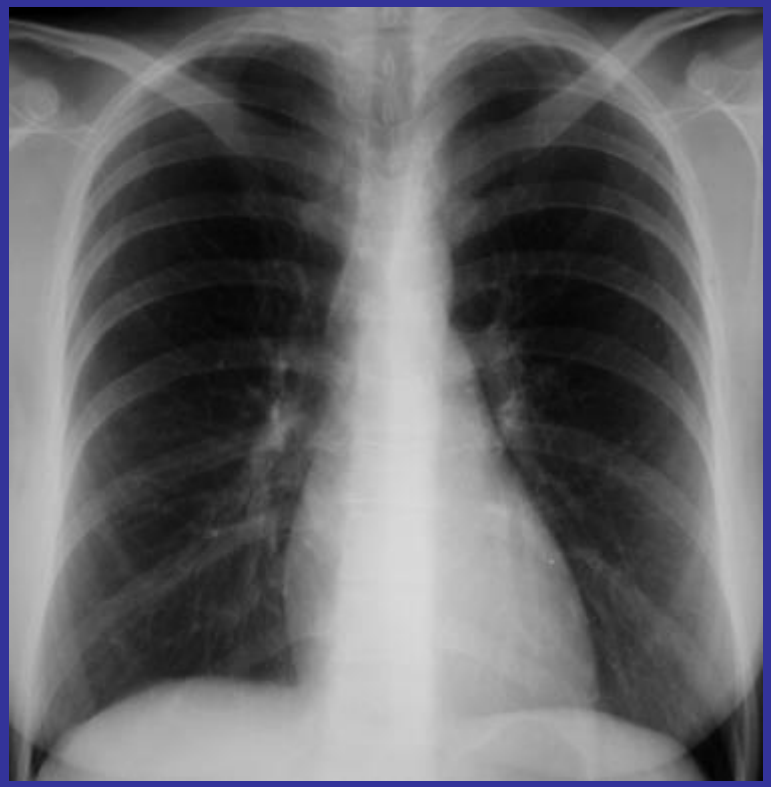

3 дня спустя

Vascular pedicle and azygos vein

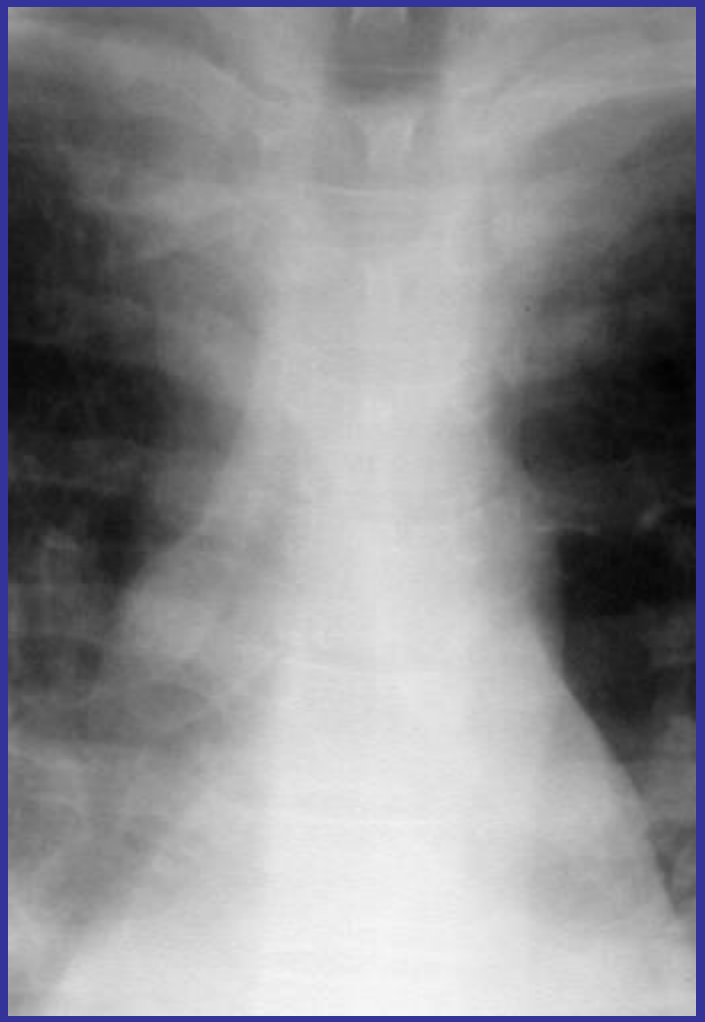

The vascular pedicle of the heart and the vena azygos.

- Ely et al. Radiologic determination of intravascular volume status using portable, chest radiography. *Crit Care Med* 2001
- Martin et al. Findings of the portable chest radiograph correlate with fluid balance in critically ill patients. *Chest* 2002
- Ely and Haponik. Using the chest radiograph to determine intravascular volume status. *Chest* 2002

Radiographic features to analyse and integrate

- Vascular pedicle and azygos vein
- ✓Heart size and shape
- Pulmonary vessels
- Pulmonary edema

Heart size and shape

- Right heart enlargement
- Left heart enlargement
- Right + left heart enlargement
- Bulging of the main pulmonary artery

Heart size and shape

Idiopathic pulmonary hypertension

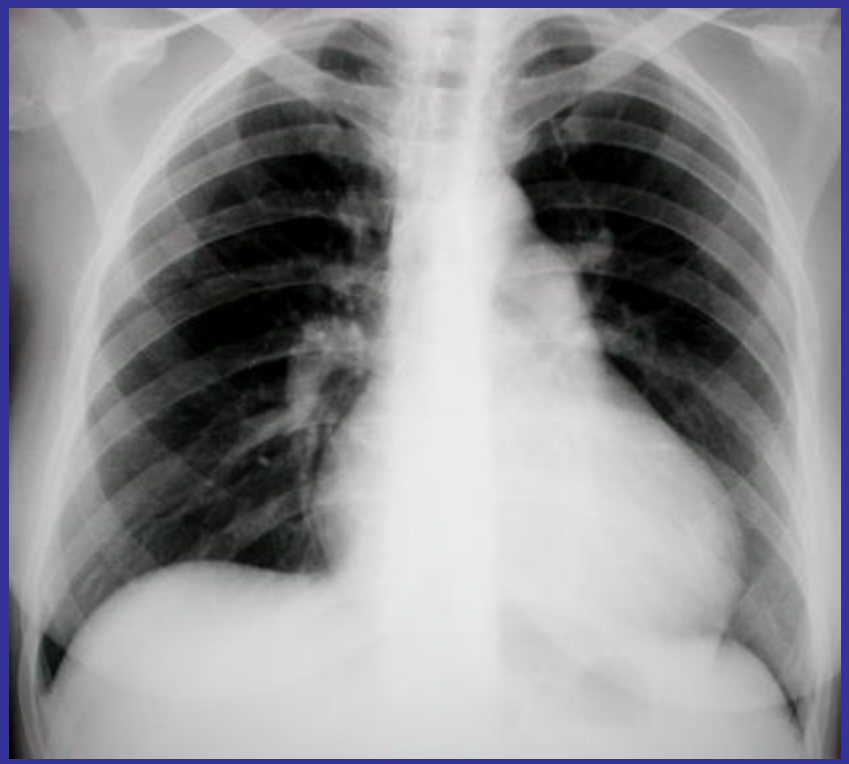

Heart size and shape

ARDS after head and long bone trauma

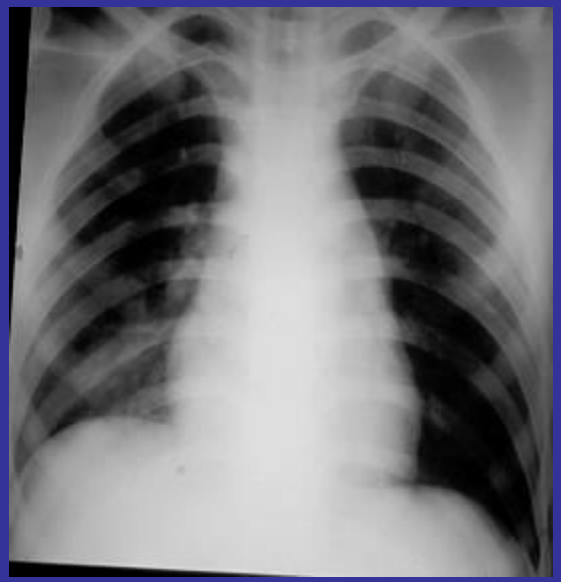

admission

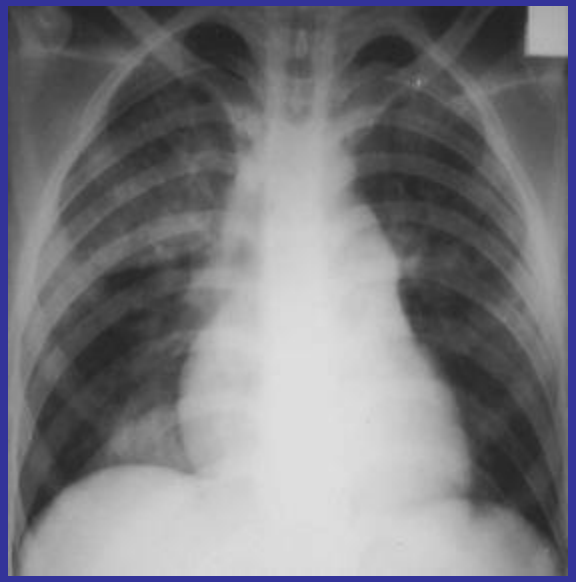

1 day later

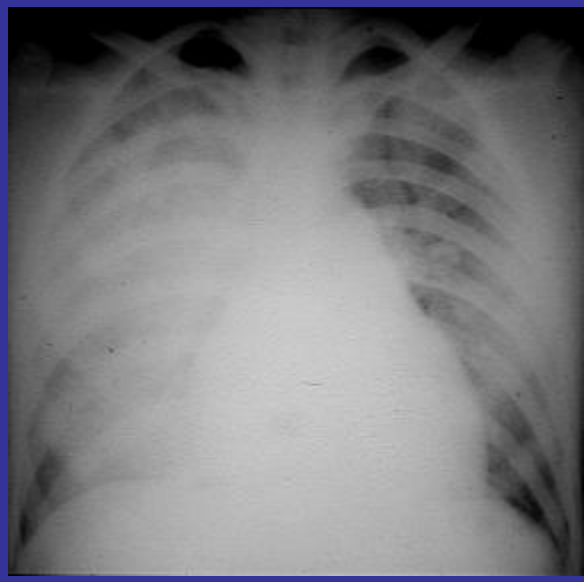

2 days later

Размеры сердца и его форма

РСДСР у больного с кровоизлиянием в мозг

поступление

Через 2 часа

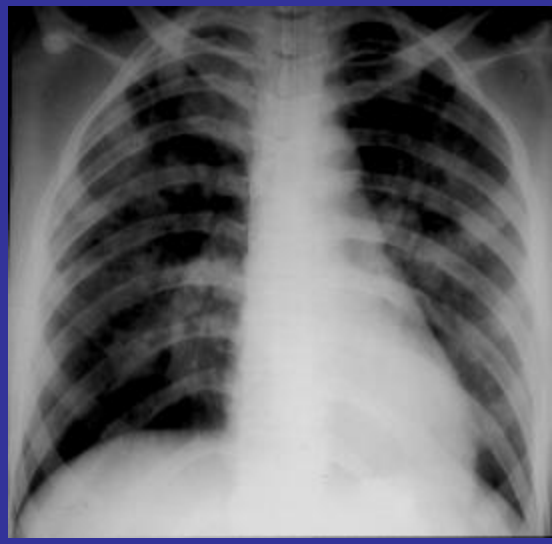

5 спустя

Размеры сердца и его форма

Массивная эмболия a. pulmonalis

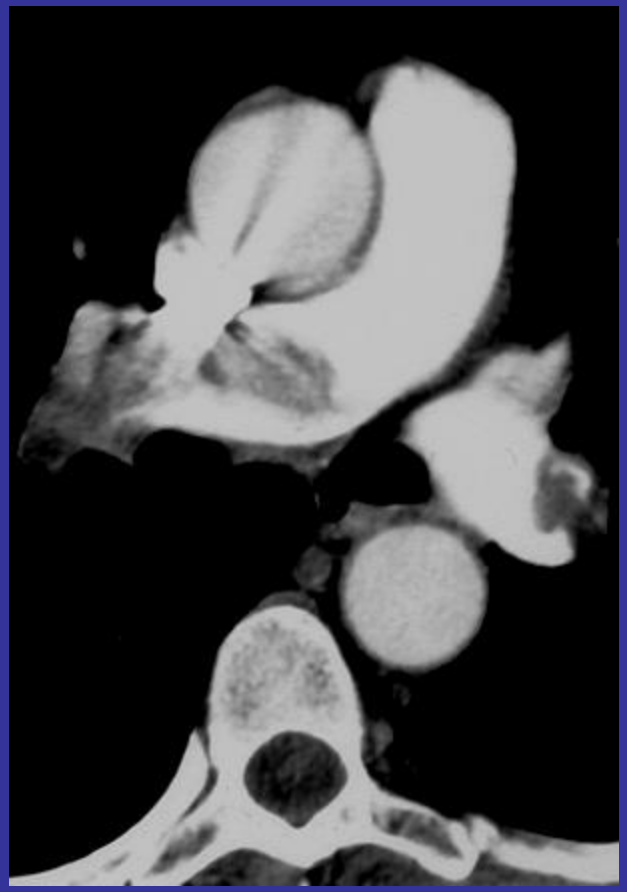

Размеры сердца и его форма

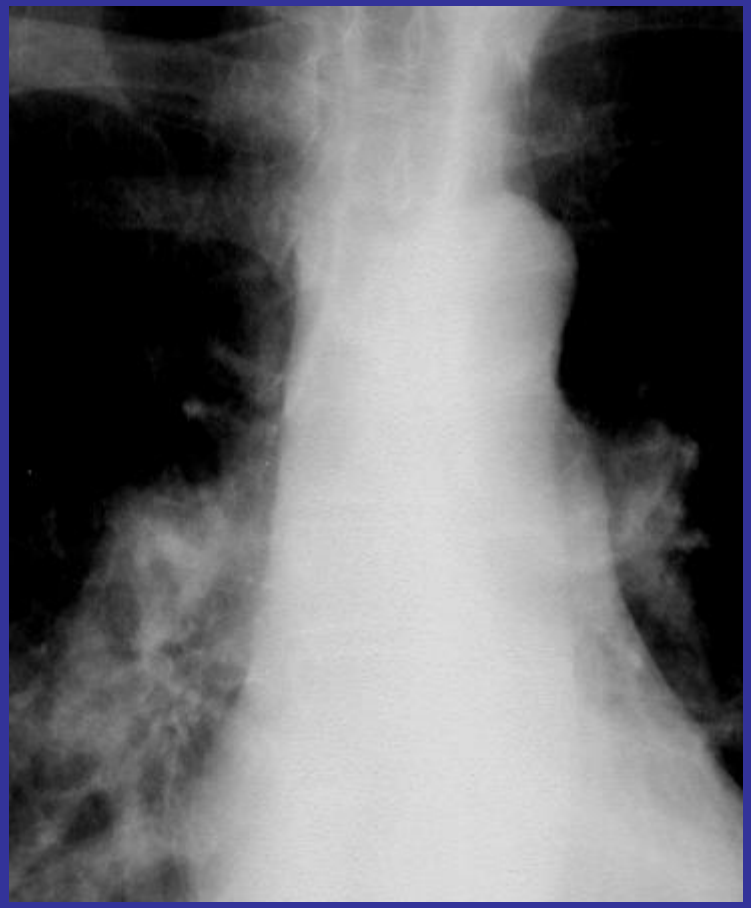

При поступлении

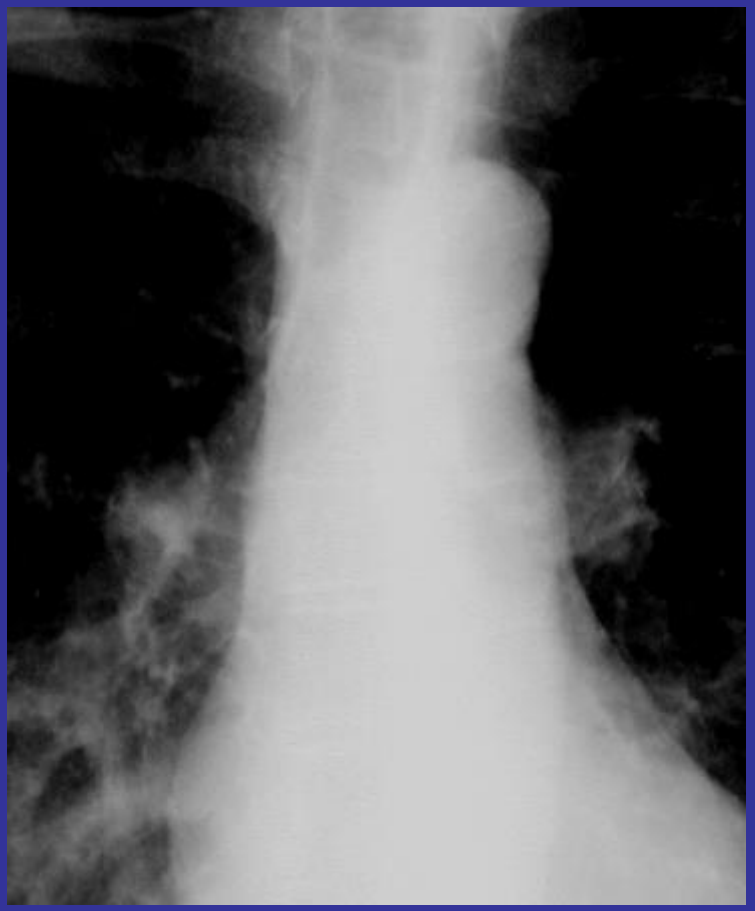

После антикоагулянтов

При поступлении

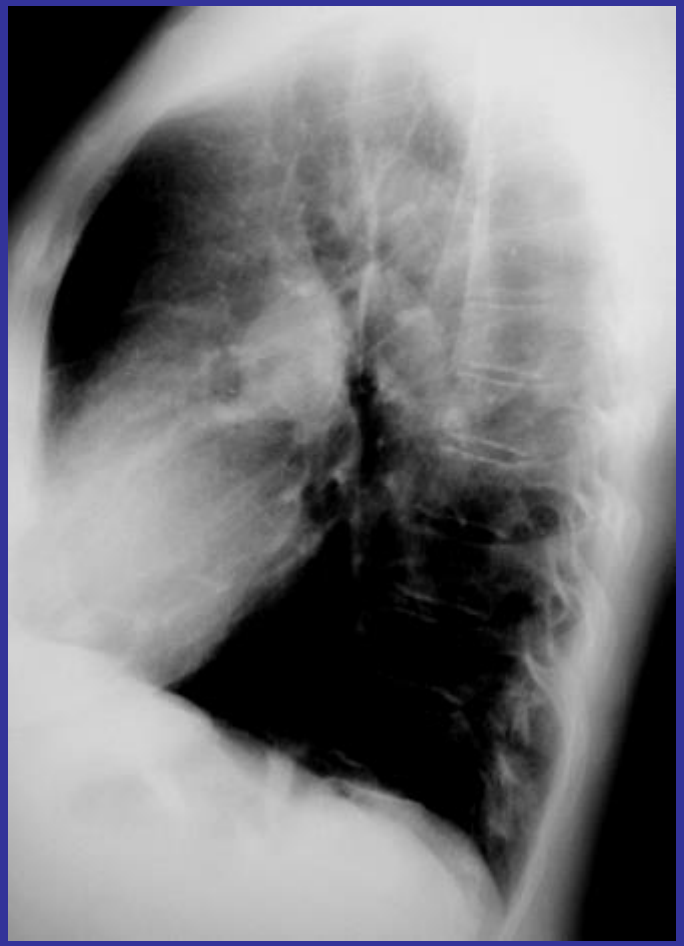

После антикоагулянтов

Radiographic features to analyse and integrate

- Vascular pedicle and azygos vein
- Heart size and shape
- ✓Pulmonary vessels
- Pulmonary edema

Pulmonary vessels

- Pulmonary blood volume and its distribution
- Central/peripheral arteries ratio
- Vascular and perivascular changes

Pulmonary vessels

Acute renal failure

admission

after dialysis

Pulmonary vessels

Intracardiac shunt

Pulmonary vessels

Intracardiac shunt

pO_2 after 30 min of 100% O_2 breathing: 151 mmHg

Pulmonary vessels

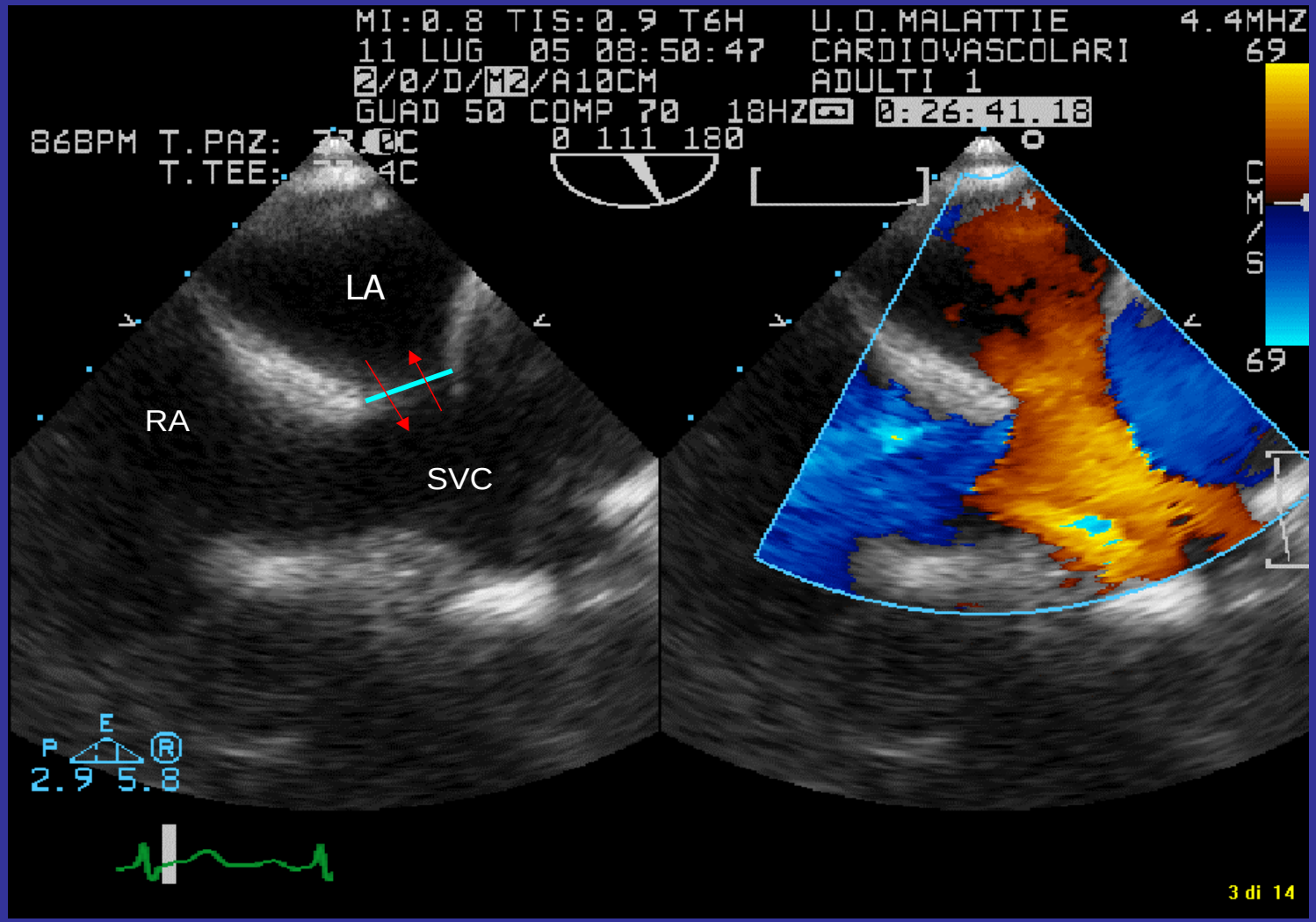

Pulmonary vessels

Left to right shunt

before

after surgery

Pulmonary vessels

Eisenmerger's syndrome

Pulmonary vessels

Pulmonary stenosis

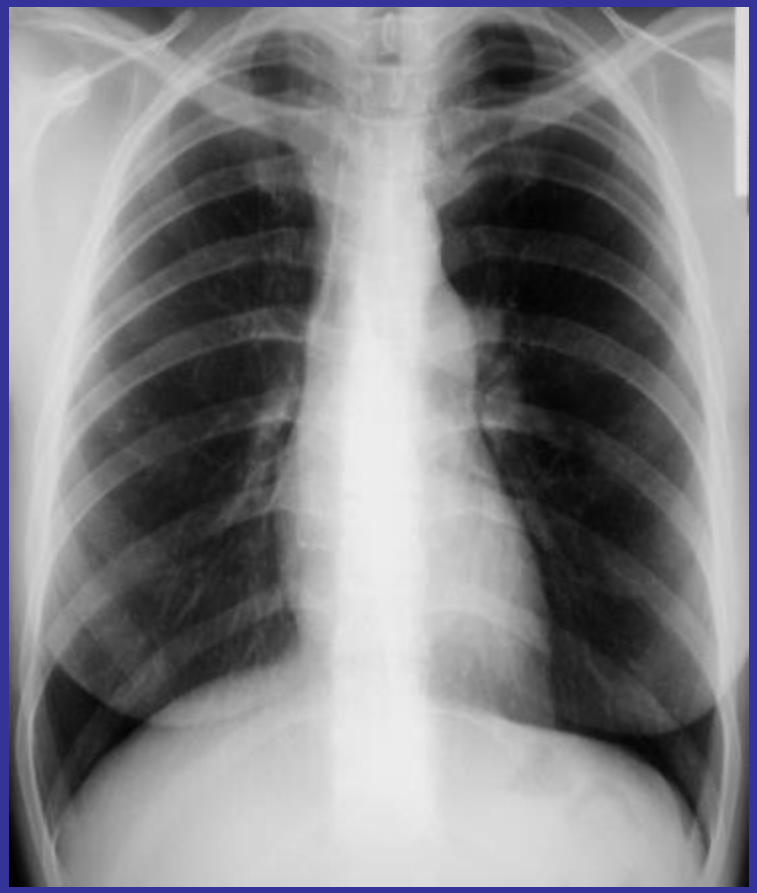

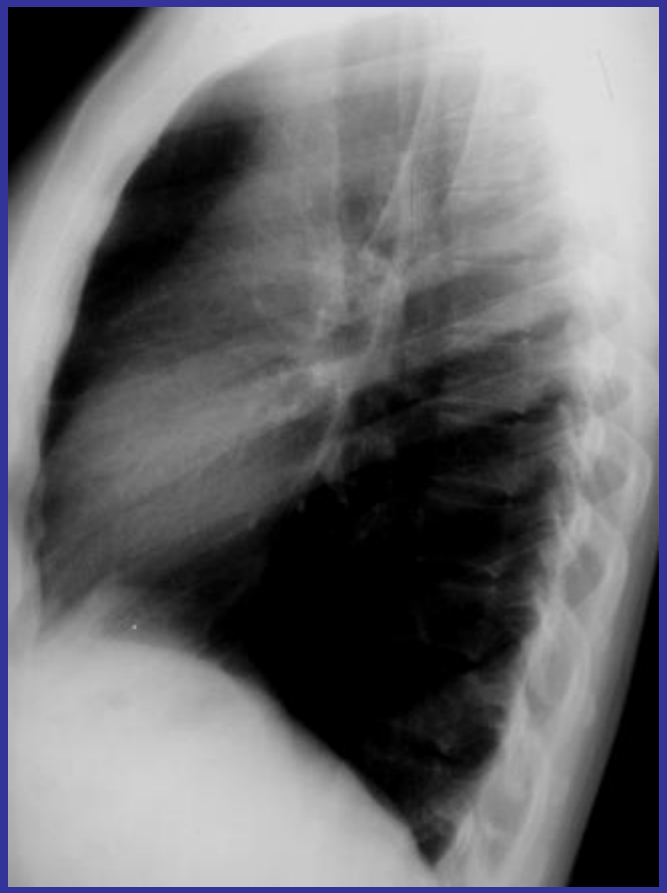

Pulmonary vessels

Pulmonary embolism

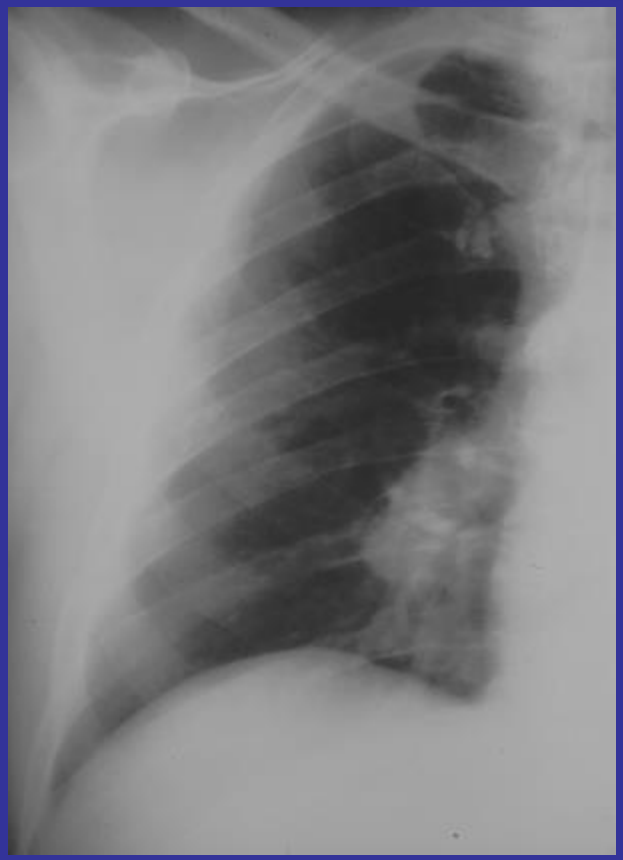

admission

after anticoagulation

Exacerbation of COPD

Exacerbation of COPD

Pulmonary edema

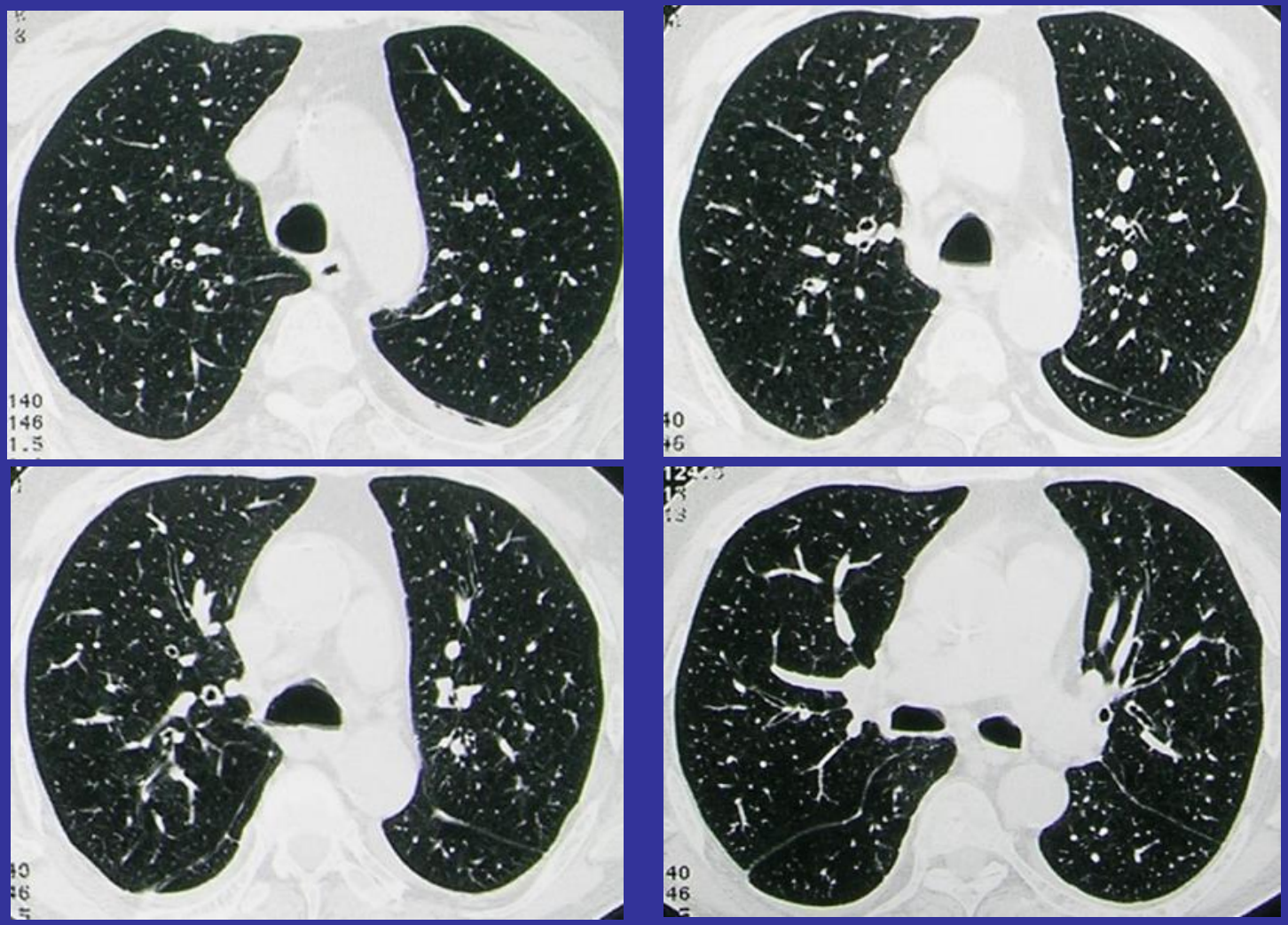

Exacerbation of COPD

Exacerbation of COPD

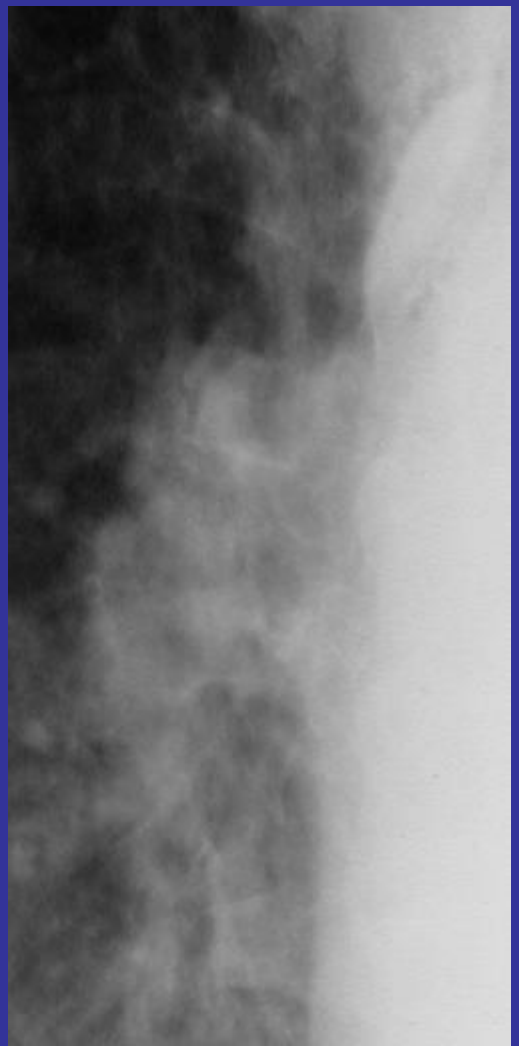

Exacerbation of COPD

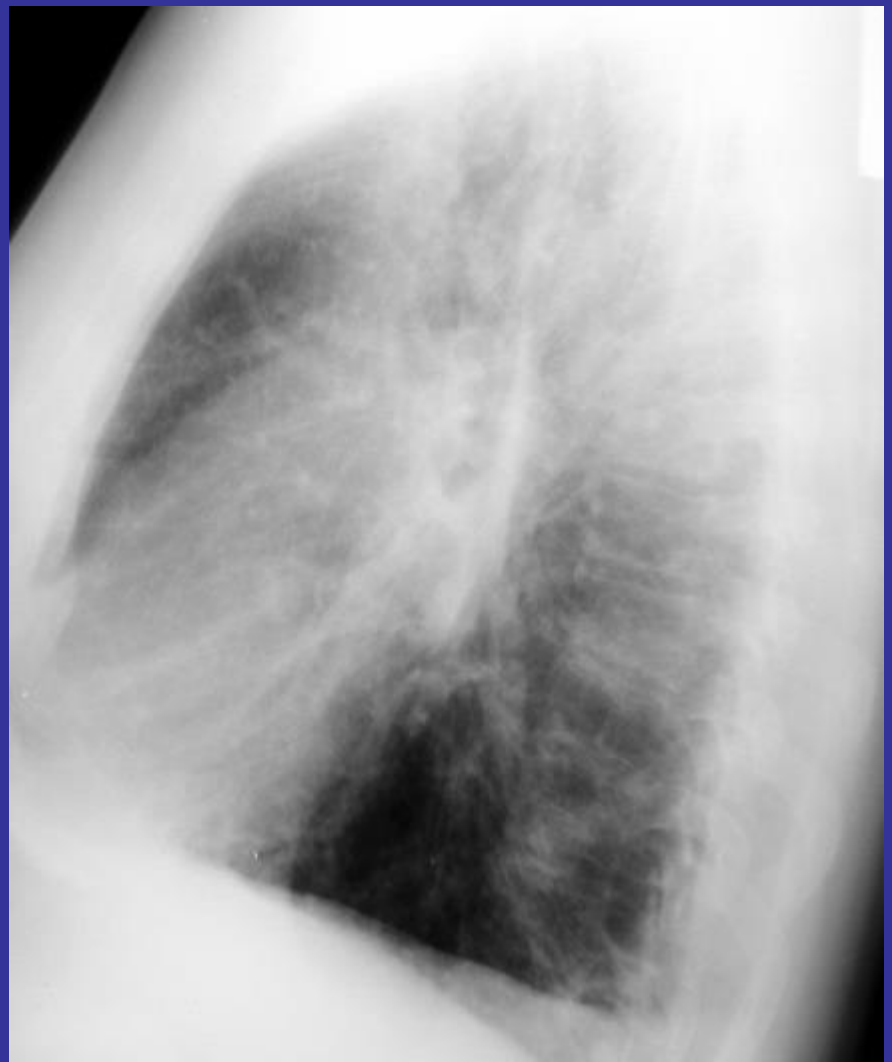

Классификация ОЛ

- Кардиогенный отек легких
- Некардиогенный отек
- Остро протекающий отек легких
- Нейрогенный отек легких
- Редкие формы отека легких

Radiographic features to analyse and integrate

- Vascular pedicle and azygos vein
- Heart size and shape
- Pulmonary vessels
- ✓Pulmonary edema

Pulmonary edema

- Etiology
  - hydrostatic
    - cardiogenic
    - overhydration
    - renal
  - injury (ARDS)
- Severity

Pulmonary edema

Pistolesi M, Giuntini C. *Radiol Clin North Am* 1978

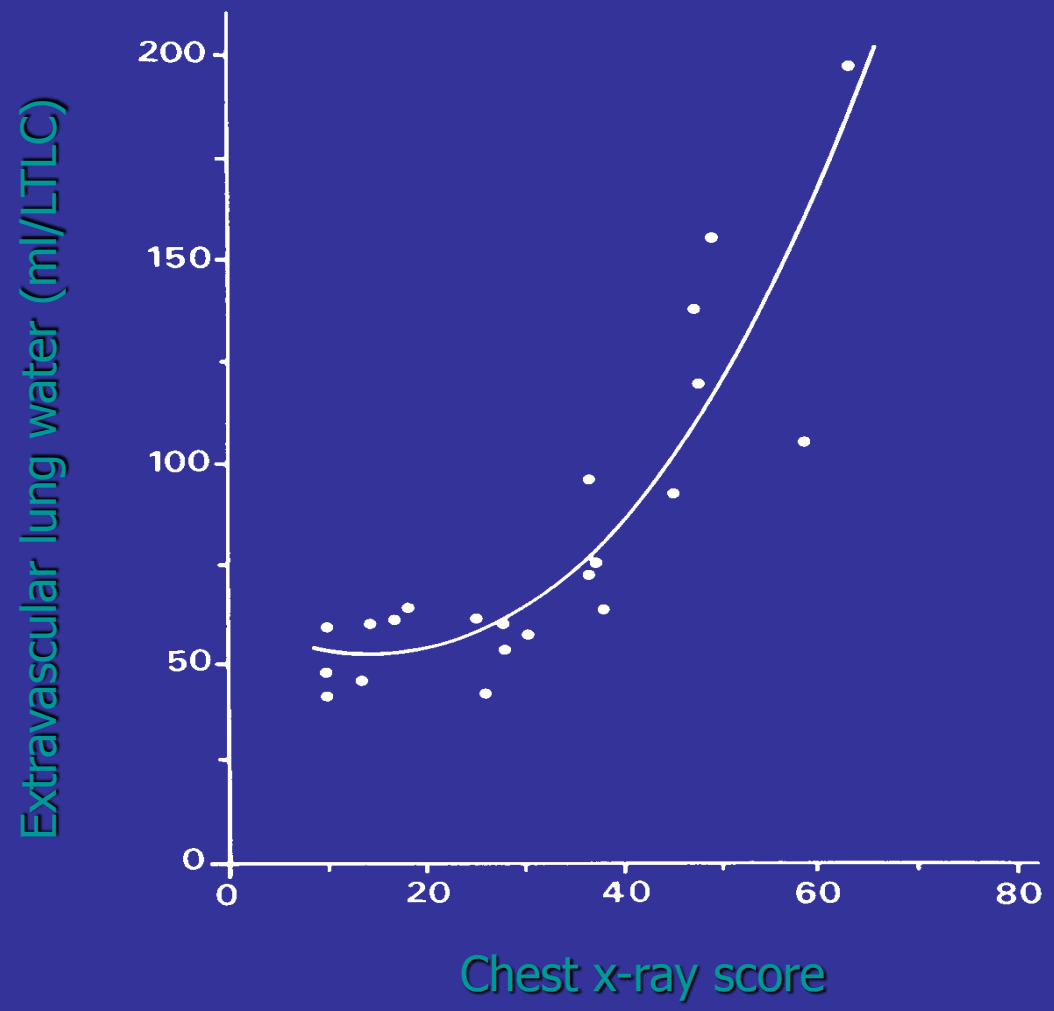

Pulmonary edema

Interstitial edema (cardiogenic)

admission

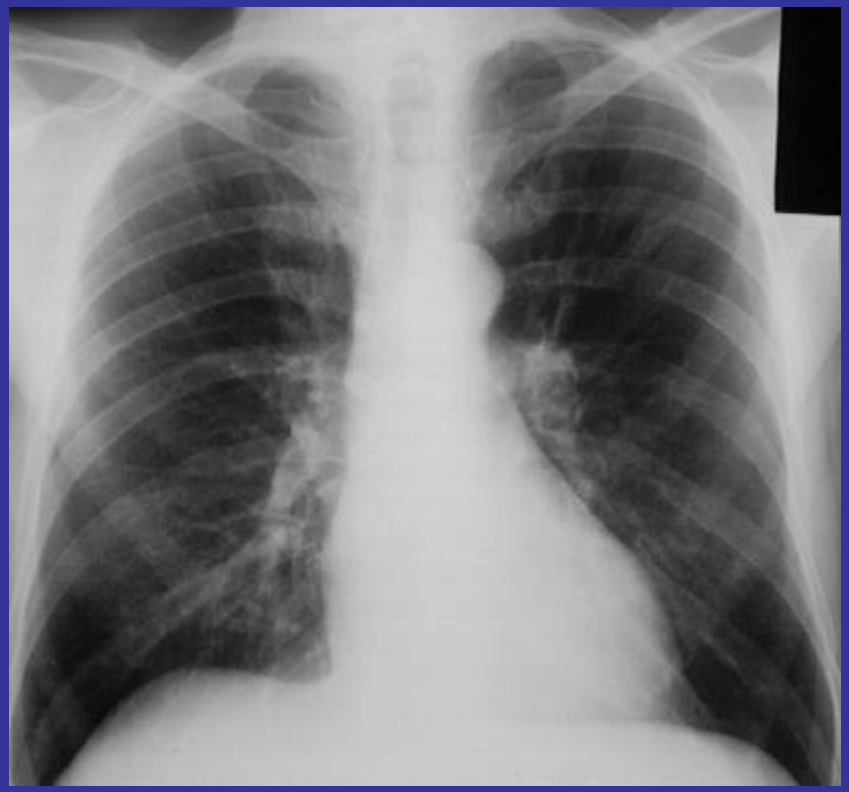

2 weeks later

Pulmonary edema

Interstitial edema (cardiogenic)

Pulmonary edema

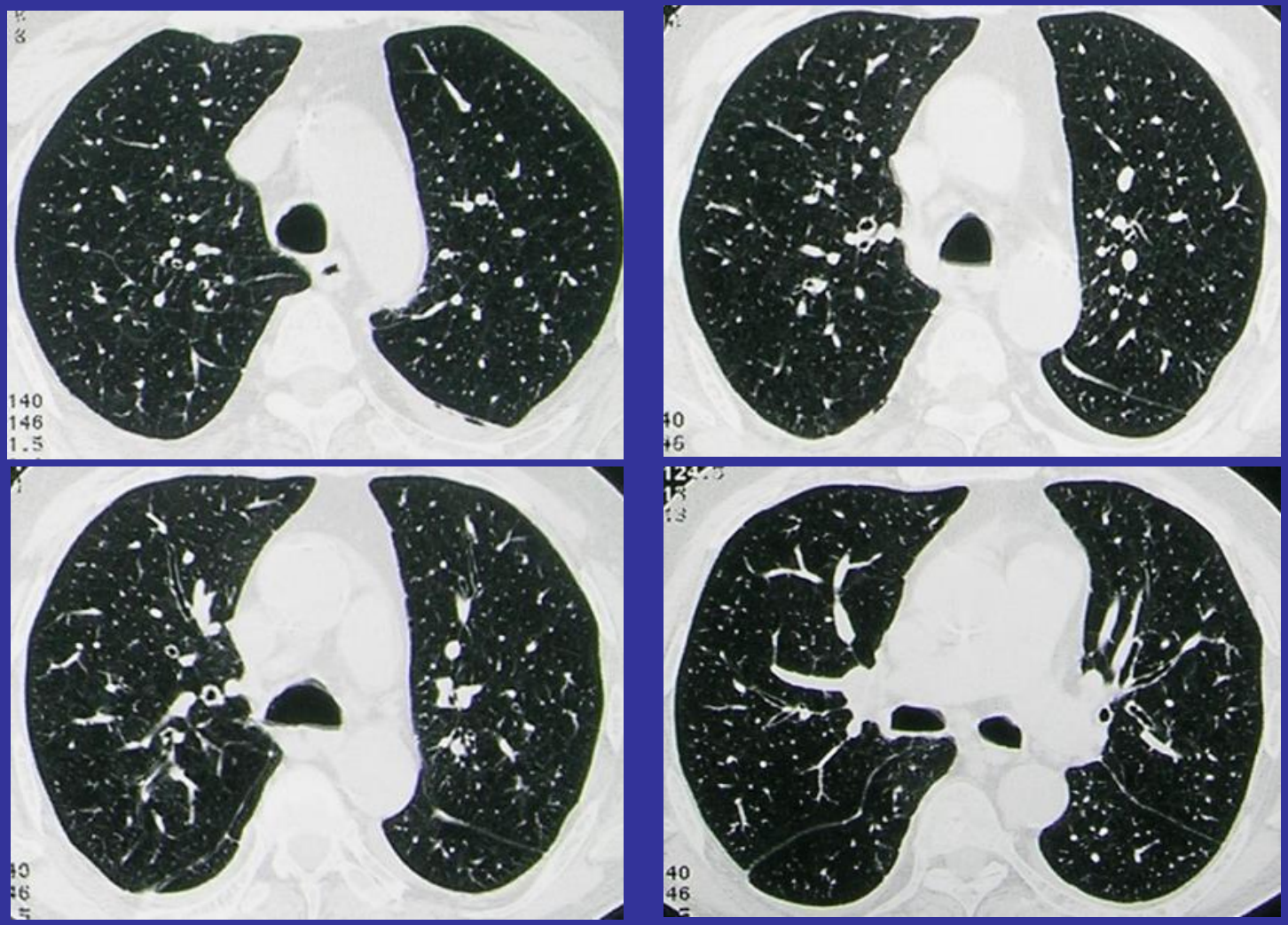

Pulmonary edema

Congestive cardiomyopathy

Pulmonary edema

Alveolar edema (cardiogenic)

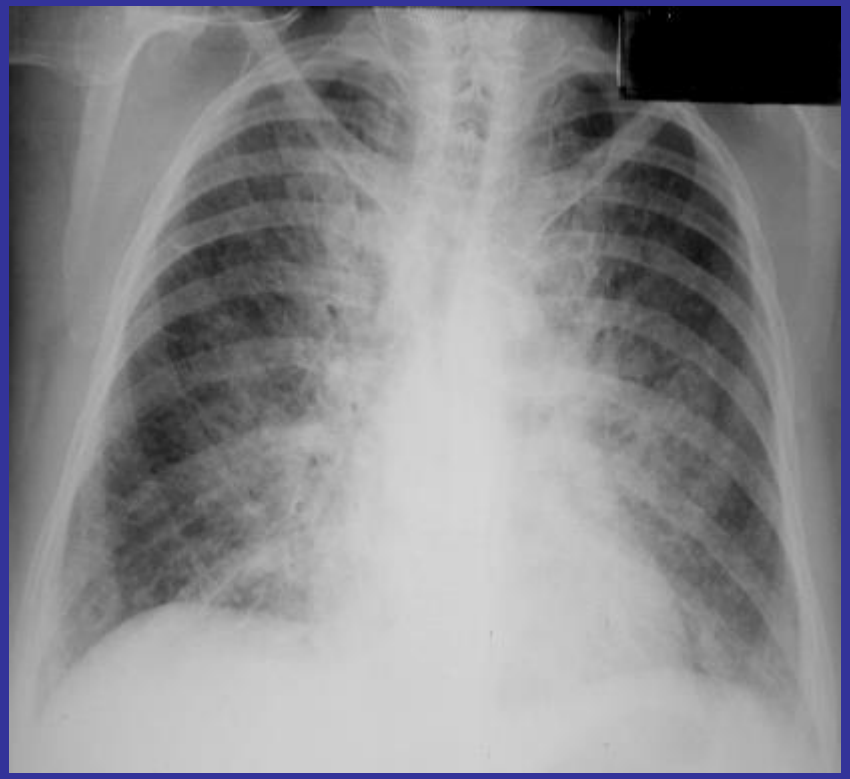

4 a.m.

9 a.m.

Pulmonary edema

Alveolar edema (cardiogenic)

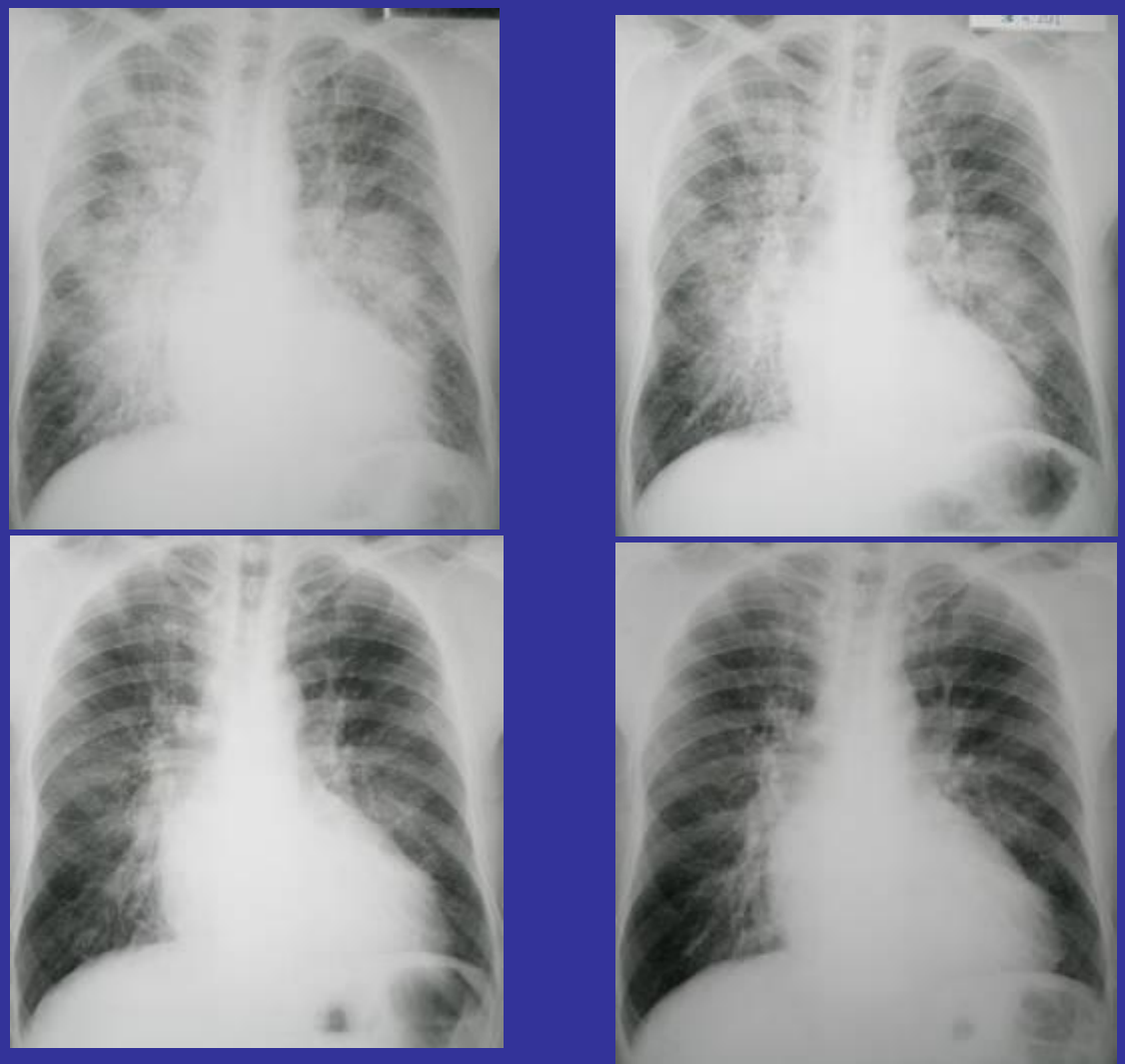

Pulmonary edema

Chronic ischemic heart failure

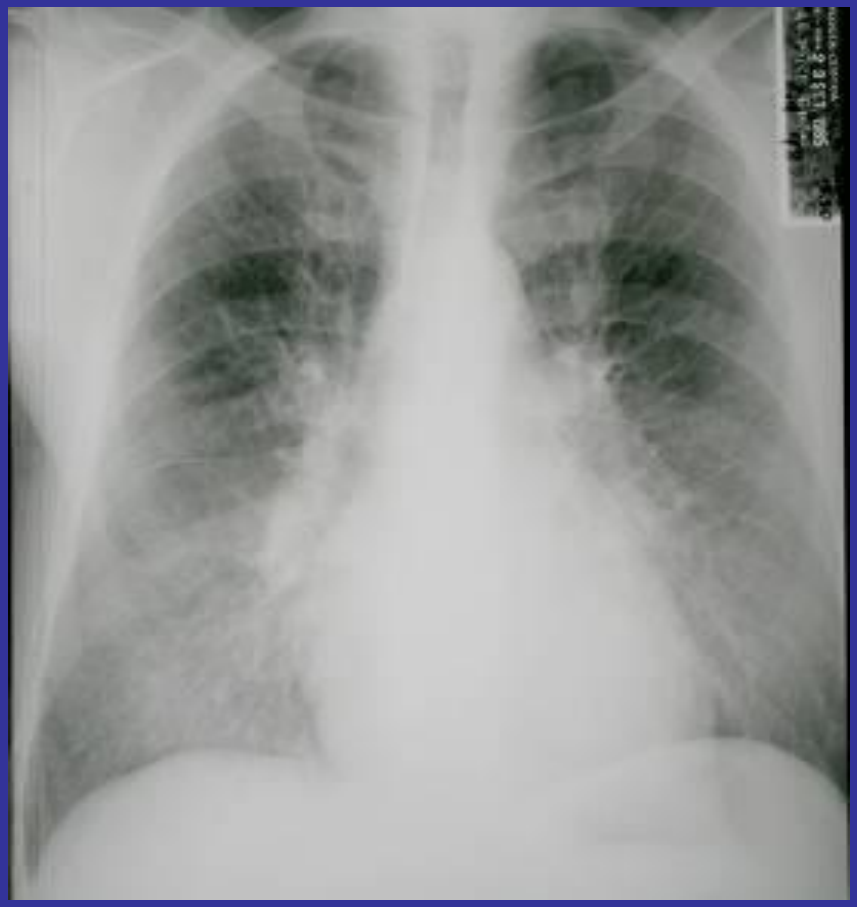

Pulmonary edema

Chronic ischemic heart failure

Pulmonary edema

Chronic ischemic heart failure

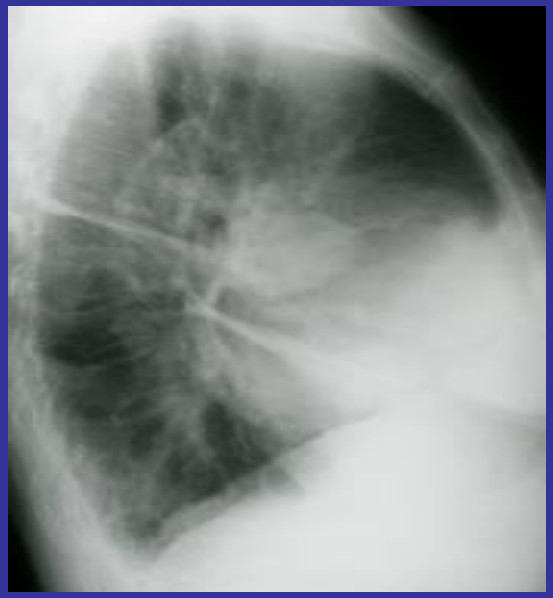

Pulmonary edema

Mitral stenosis

Pulmonary edema

Alveolar edema (cardiogenic)

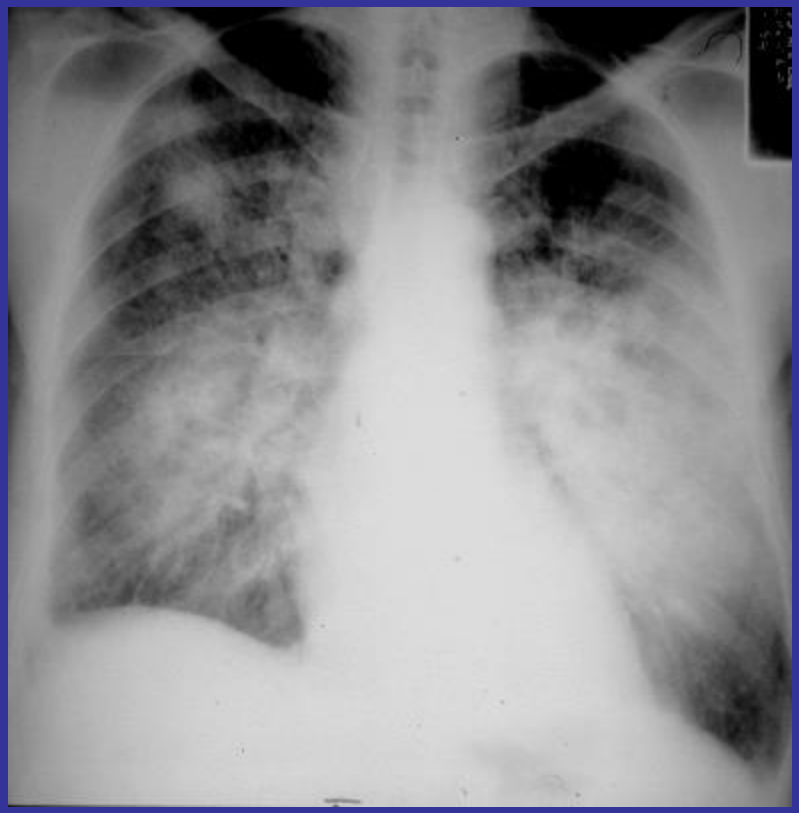

After mitral valve replacement

Pulmonary edema

Acute myocardial infarction

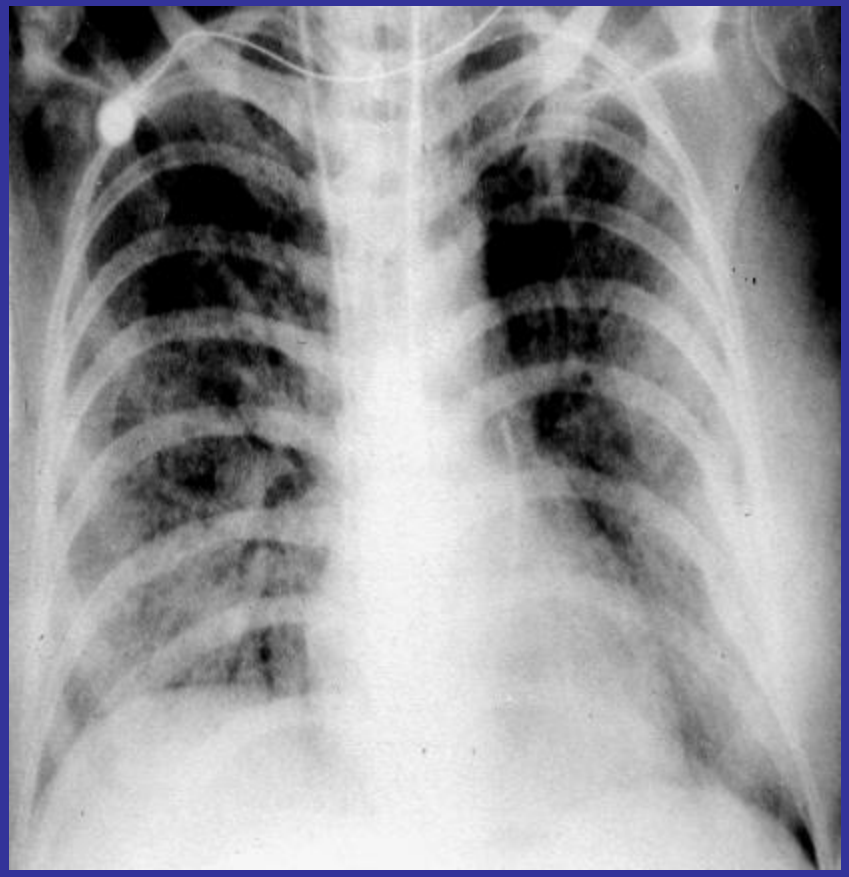

ARDS after sepsis

Pulmonary edema

Alveolar edema (ARDS)

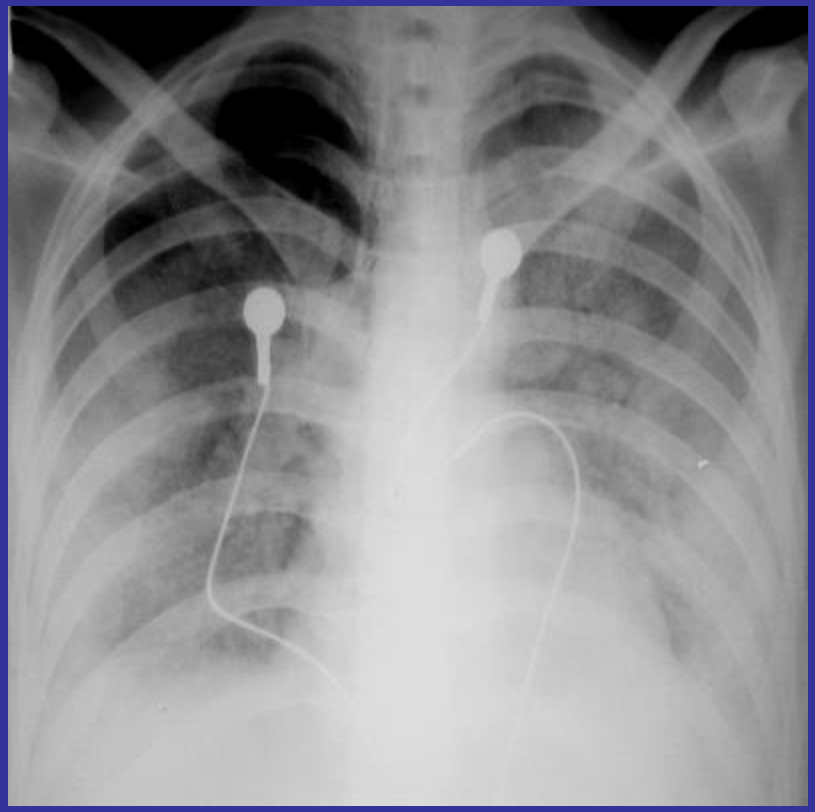

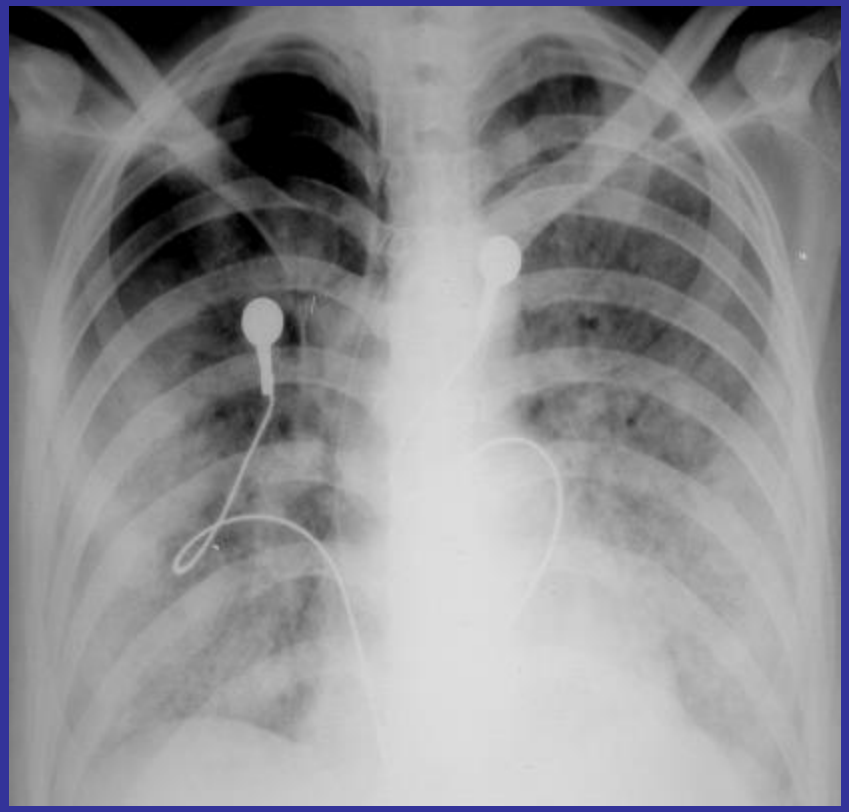

5 days later

Radiographic features to analyse and integrate

- ✓ Vascular pedicle and azygos vein
- ✓ Heart size and shape
- ✓ Pulmonary vessels
- ✓ Pulmonary edema

- Evaluation of body fluids balance
- Right and left heart failure
- Pulmonary hypertension
- Pulmonary embolism
- Evaluation of COPD
- Cardiogenic and noncardiogenic pulmonary edema

"*Seeing*" is based on the information content of the object, "*perceiving*" on the information content of the observer.

The film reader with a knowledge of cardiopulmonary pathophysiology is better able to determine why a particular radiographic pattern occurs and therefore to explain its functional significance.

Milne ENC, Pistolesi M. ***Reading the Chest Radiograph. A Physiologic Approach***. St.Louis, Mosby-Year Books, 1993.